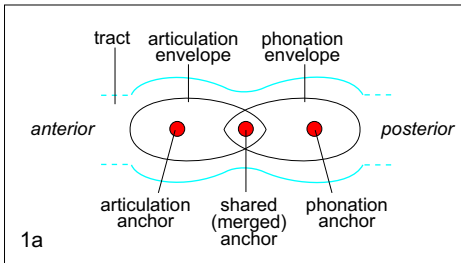


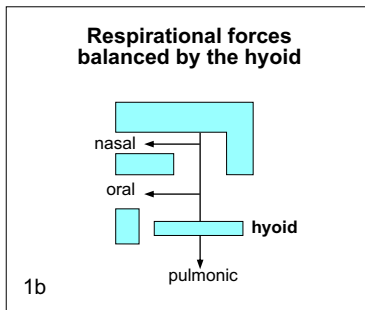
2. PHONATION - The anchor-envelopes of articulation and phonation

Introduction The phonation anchor-envelope system is more difficult to analyze than the articulatory one and here only some general features can be given. The uncertainty of the exact serial order placement of the epiglottic valve along the tract is one example of ambiguity and reason for possible errors of details in the following. Much further research is needed in this topic.

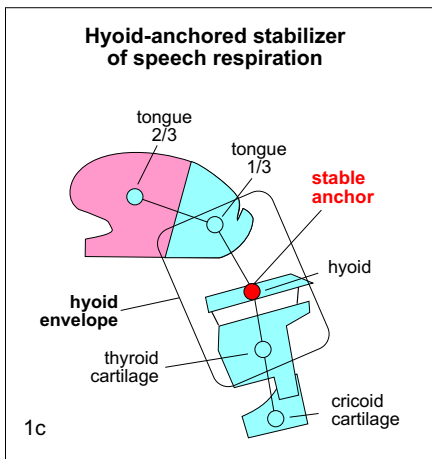


1. Anchor-envelopes of articulation and phonation

Both articulation and phonation possess particular anchor-envelopes. The two can be seen as consecutive segments in (meta)peristaltic sequence that are united through a shared/merger anchor, as antagonist segments always are. Cf., center of mass between multiple starts. fig. 1a.



The **hyoid** is the essential mediator that balances the upper and lower antagonist forces of **respiration**. The lower one is the primary pulmonic action and the upper one consists of the pair of oral and nasal antagonists, or compensating agents. fig. 1b.

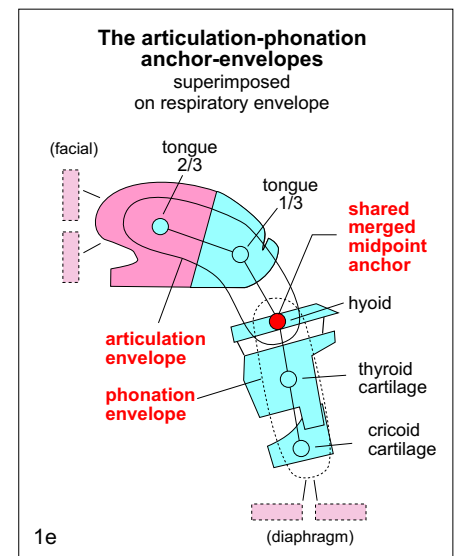
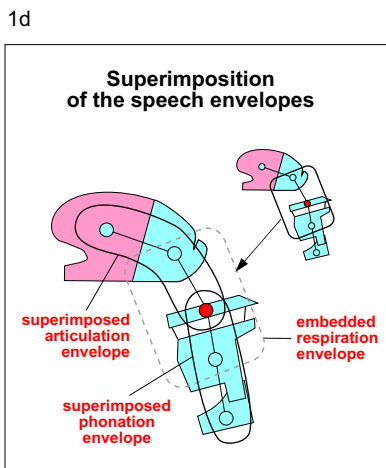


Because the respiration framework remains embedded in speech, **speech respiration** retains the **hyoid** as its central balancing anchor. The anchors of the pharyngeal 1/3 tongue, of the hyoid and of the thyroid cartilage form the trimeric, or three part anchoring of the envelope. The hyoid is the stable anchor shared by the frameworks of both speech and embedded respiration. Also see below Phonation Appendix, Hyoid symmetries. fig. 1c.

Initiation of the **general speech** framework **superimposes** the combined articulation-phonation anchor-envelope, which remains embedded, over the respiratory one. fig. 1d.

The hyoid is still the **shared** central anchor, but the entire tongue and larynx also become active. The framework, in addition, expands as anteriorly the circumoral-facial-cranial (or hypobranchial) sheet and the mandible and caudally the esophagus and diaphragm are joined to the active framework. **Fig. 1e** shows the map of this axial anchor-envelope merger. Also see page 4 on the symmetrical relation of the facial (hypobranchial) and diaphragm sheets.

The anchors of the **articulation** envelope are those of the tongue 2/3, the tongue 1/3 and the hyoid; the anchors of the **phonation** anchor are those of the hyoid, and the thyroid and cricoid cartilages. Productions of specific phonemes additionally superimpose their own sub-frameworks over this configuration, which remains enfolded.



1d

1e

2. Speech respiration and active speech envelope primacies

The articulation and phonation envelopes form a coactive antagonist pair. **Primacy** (or prime movement or agency) is an important variable in antagonist relations. In static speech **respiration**, which occurs when drawing breath between phrases, the primary agent is the **phonatory** envelope, and the articulatory one is secondary, or antagonist. In active **speech** the oral region becomes the **articulatory** envelope and it attains primacy. fig. 2a.

Examples of primacy superimposition patterns in phoneme production

Voicing

In the production of the **isolated** anchor of a stop, like /t/, **primacy** resides in the articulatory envelope. (The condition of the phonatory envelope and of the other tract stricture valves for /t/ is difficult to ascertain due to their locked, immobile state.) fig. 2b.

The tongue shaping of /s/, which opens a narrow channel for airflow is a modification of the full tract obstruction of the /t/ stop, and it is created through merger of the /t/ and /n/ anchors. (Cf. the t-n-k/(d-n-g) trianchor in *Mastication* and *Speech Ontogeny*. Mergers of various positional variants of base anchors t and n produce the anchors of the th, ts, t, sh palatals; k and n mergers create kh and other velars. This is one of the alternate manners of consonant production).

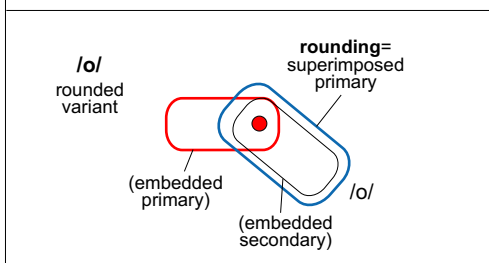
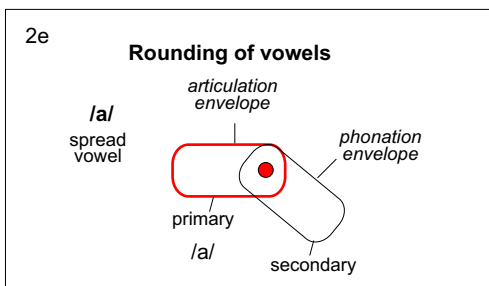
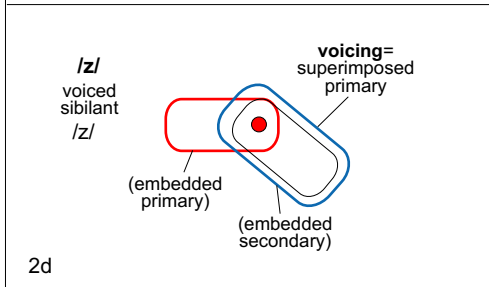
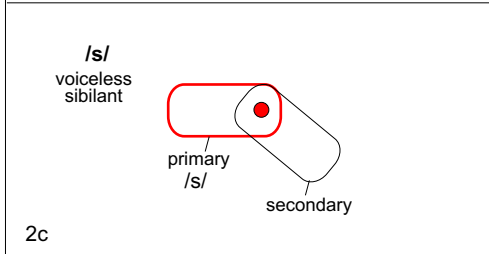
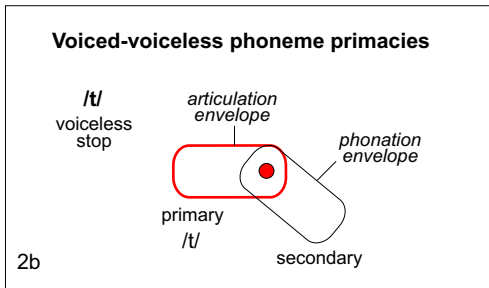
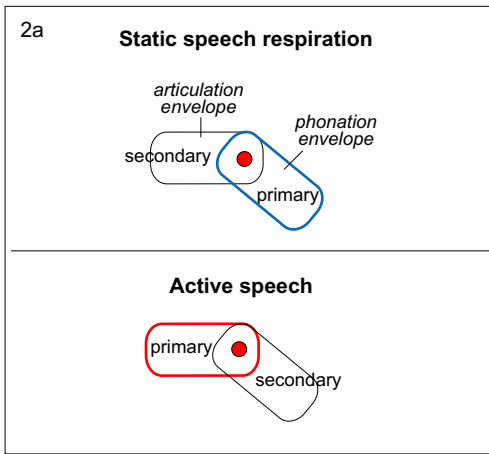
In producing the anchor of the **voiceless** /s/ the articulating envelope is still **primary**. But some phonation envelope activity is now observable: there is partial glottis opening. This is observable when **after** generating an /s/ the articulatory anchor is released and only the phonatory envelope remains active. fig. 2c.

In producing the anchor of /z/, the **voiced** counterpart of /s/, a new temporary **primacy** is superimposed on the phonatory envelope, whereby the increased energy level further constricts and otherwise modifies the glottis to execute voicing. The articulatory envelope is now secondary. Phonation, that is glottal oscillation is now observable. On releasing the /z/ anchor its increased energy state decays to the antecedent /s/ configuration. fig. 2d.

A similar superimposed **phonatory** envelope primacy occurs when voiceless /t/ is voiced to become /d/. The same superimposition but of different proportion of the antagonist forces takes place in the case of the partially voiced /t/, alternately called devoiced /d/ of Chinese and related languages.

Rounding

An **reversal** of primacy between articulatory and phonatory envelopes occurs also in vowel **rounding**. That is, for a spread vowel the articulatory envelope is primary, but when primacy is shifted to the phonatory envelope, that vowel becomes **rounded**. Technically speaking, voicing of a consonant is the **analog** of vowel rounding. fig. 2e.

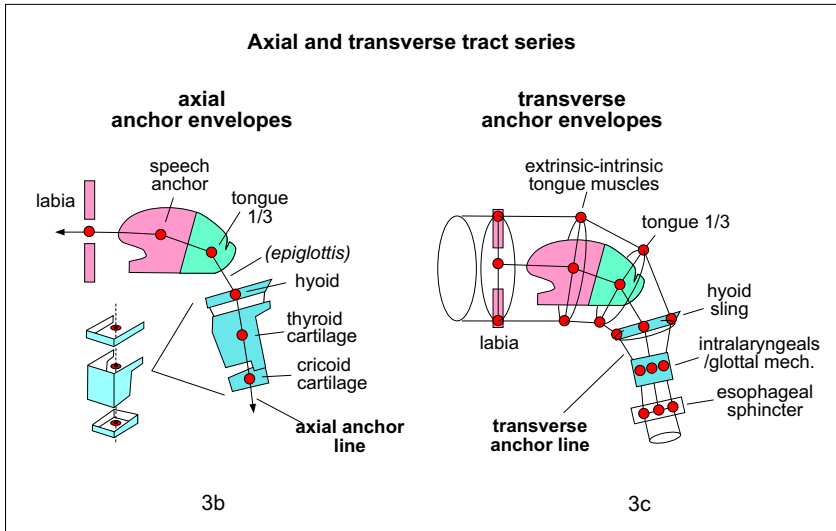
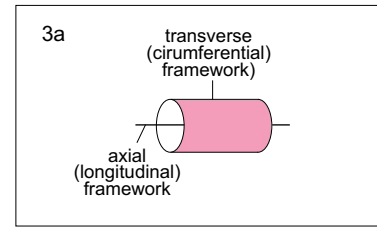


Notes on axial-transverse upper visceral tract structure

Articulation and phonation are functions of the composite structure of the cylindrical UV tract. Articulation is a force framework assigned to the axial-longitudinal tract component while phonation is assigned to the transverse-circumferential one. fig. 3a.

Phonation decreases the tract cross-section at the glottis to the point of generating air flow oscillations. It may be said that technically, the tongue and the velum are also devices of phonation as they provide additional air oscillation for fricatives such as /s/ or trills such as the lingual and velar /r/'s.

Model of UV tract structure



Transverse tract—qualifications

The **cylindrical** tract is longitudinally less uniform than the linear one. Anteriorly the labia, the mandible and the tongue can significantly modify the cross section. Moving posteriorly, this capability decreases: the pharynx has more limited transverse size variation and the thyroid-cricoid cartilage has practically none. However, in the larynx the transverse modulation moves medially to the the intralaryngeal glottal framework, which now performs cross-sectional changes.

This exchange of behaviors between outer and inner UV tact components may be seen as a **role reversal** of the axial and transverse tracts past the laryngeal pharynx, where the action of the circumferential tract becomes linear, since the tract housing comprised of the thyroid and cricoid cartilages can essentially only move in axial directions, while the axial line medial in the larynx, that is, the intralaryngeal thyro-arytenoid structure takes on cross section manipulation. The hyoid the divider of the two sections. fig. 3d.

This role reversal appears structural once reaching the two layers of the esophagus, where the outer one is composed of longitudinal fibers and the inner one of circular ones.

Axial tract anchor-envelope series

The axial line anchors include those of the following regions: the labial, tongue 2/3, tongue 1/3, (epiglottal), hyoid, thyroid cartilage and cricoid cartilage. Some of the axial anchors are situated on the line running through the empty center of the structures, that is, they occur at the nodal concurrence of forces. The exact placement of the epiglottis on the axial line is uncertain: this organ lies neither before or after, but approximately within the transverse plane of the hyoid bone. fig. 3b.

Transverse tract anchor-envelopes series

The transverse line anchors include the central anchors of the tract sections situated at: the labial circumference, the transverse sectional frames of forces acting on the lingual 2/3 and 1/3, on the hyoid, on the glottal (thyro-crico-arytenoid subframework), on the thyroid and on the cricoid cartilages. The last one may be more accurately described as the anchoring of the upper esophageal sphincter. The axial and at the same time transverse muscles of the thyroid cartilage are those connecting it to the sternum and the pharyngeal walls. Although these are mainly axially extended, they also pull the thyroid transversely. (The sternohyoid, the sternothyroid and omohyoid straps are somewhat oblique in relation to the body axis and so they move the hyolarynx both axially and transversely.) Only anchors in sagittal plane are shown for simplicity. fig. 3c.

Role reversal

